



# Mastoiditis Due to *S. pneumonia* 19A in a Fully Vaccinated Child

Tam Aşılı Bir Çocukta *S. pneumonia* 19A'ya Bağlı Mastoidit

Seval Özen<sup>1</sup>(ID), Belgin Gülhan<sup>1</sup>(ID), Aslınur Özkaya Parlakay<sup>1</sup>(ID), Bengi Arslan<sup>2</sup>(ID), Mesut Sivri<sup>3</sup>(ID), Mine Dedeoğlu<sup>4</sup>(ID), Saliha Kanık Yüksek<sup>1</sup>(ID)

<sup>1</sup> Clinic of Pediatric Infectious Diseases, Ankara City Hospital, Ankara, Türkiye

<sup>2</sup> Clinic of Otorhinolaryngology, Ankara City Hospital, Ankara, Türkiye

<sup>3</sup> Clinic of Radiology, Ankara City Hospital, Ankara, Türkiye

<sup>4</sup> Clinic of Pediatrics, Ankara City Hospital, Ankara, Türkiye

**Cite this article as:** Özen S, Gülhan B, Özkaya Parlakay A, Arslan B, Sivri M, Dedeoğlu M, et al. Mastoiditis due to *S. pneumonia* 19A in a fully vaccinated child. *J Pediatr Inf* 2023;17(4):e277-e280.

## Abstract

*Streptococcus pneumoniae* is a prevalent cause of pediatric acute otitis media (AOM) cases. Mastoiditis continues to be a significant complication of AOM. Data obtained following the use of 13-valent pneumococcal conjugate vaccines (PCV13) have shown that in children with AOM, PCV13 serotypes from tympanocentesis or spontaneous ear drainage decrease and the probability of colonization of PCV13 serotypes in the nasopharynx is lower. In this paper, we aimed to report a case of mastoiditis and subperiosteal abscess caused by the *S. pneumoniae* 19A serotype that is penicillin resistant developing in a three-year-old patient with full PCV13 vaccination and normal immunity. Although PCV13 is included in the National Immunization Program of Türkiye, penicillin resistant *S. pneumoniae* serotype 19A should be kept in mind as a potential cause in complicated mastoiditis cases in patients with full PCV13 vaccination who have normal immunity.

**Keywords:** Serotype 19A, mastoiditis, acute otitis media, pneumococcal conjugate vaccine (PCV13)

## Introduction

Acute mastoiditis is a suppurative complication of acute otitis media, which develops as a result of the infection of mastoid air cells in the temporal bone. Mastoiditis frequently requires hospitalization and intravenous antibiotic treatment

## Öz

*Streptococcus pneumoniae*, çocuklarda akut otitis medianın (AOM) yaygın bir nedenidir. Mastoidit, AOM'nin önemli bir komplikasyonu olmaya devam etmektedir. On üç valanlı konjuge pnömokok aşılarının (PCV13) kullanımı sonrasındaki veriler, AOM'li çocuklarda timpanosentez veya spontan kulak drenajından PCV13 serotiplerinin azaldığı ve nazofarenkste PCV13 serotiplerinin kolonizasyon olasılığının daha düşük olduğunu göstermiştir. Bu yazımızda, üç yaşında, tam doz PCV13 aşılı ve bağışıklığı normal bir hastada gelişen penisilin dirençli *S. pneumoniae* 19A serotipinden kaynaklanan akut mastoidit ve subperiosteal apse vakasını sunuyoruz. PCV13, Türkiye'nin Ulusal Bağışıklama Programı'nda yer almasına rağmen, bağışıklığı normal olan komplike mastoidit vakalarında, penisilin dirençli *S. pneumoniae* serotip 19A potansiyel bir neden olarak akla gelmelidir.

**Anahtar Kelimeler:** Serotip 19A, mastoidit, akut otitis media, pnömokok konjuge aşısı (PCV13)

and/or surgical intervention. If not immediately treated, it can cause serious complications such as deep neck infections, meningitis, abscess formation (subperiosteal, epidural, or subdural), sigmoid sinus thrombosis, and hearing loss (1).

The routine 7-valent pneumococcal conjugate vaccine (PCV7) has reduced the incidence of invasive and non-invasive

## Correspondence Address / Yazışma Adresi

Seval Özen

Ankara Şehir Hastanesi,  
Çocuk Enfeksiyon Hastalıkları Kliniği,  
Ankara, Türkiye

E-mail: drsevalcevik@hotmail.com

Received: 07.12.2022

Accepted: 04.02.2023

Available Online Date: 22.12.2023

pneumococcal diseases in children to a large extent worldwide (2). PCV7 was licensed in 2000, and it contains the 4, 6B, 9V, 14, 18C, 19F, and 23F serotypes of *Streptococcus pneumoniae*. PCV10 includes the 1, 5, and 7F serotypes in addition to those in PCV7. In addition to the serotypes in PCV10, the PCV13 vaccine includes the 3, 6A, and 19A serotypes, and it was licensed by the European Medicines Agency in 2009 (3). PCV7 was added to the National Immunization Program in Türkiye in November 2008, and based on the local seroepidemiology of invasive pneumococcal disease, it was replaced by PCV13 in November 2011. While it had been administered in four doses in children at the end of the second, fourth, sixth, and 12<sup>th</sup> months after birth until 2019, by 2019, it started to be included in the National Pediatric Vaccination Schedule of Türkiye in the form of three doses administered at the end of the second, fourth, and 12<sup>th</sup> months of life (4).

In this article, we aimed to report a case of acute mastoiditis and subperiosteal abscess caused by the penicillin resistant *S. pneumoniae* 19A serotype that developed in a three-year-old patient with normal immunity who had been administered four doses of PCV13 before schedule change.

### Case Report

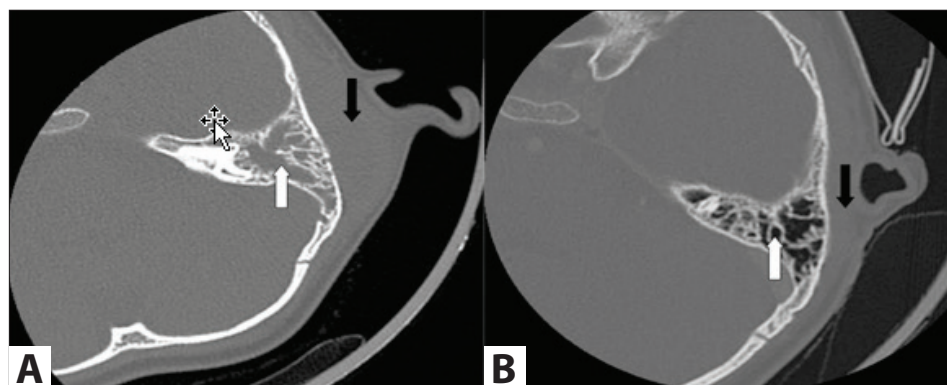
A three-year-old male patient was admitted to our hospital due to fever ongoing the last 10 days and swelling behind his ear. It was learned that he had been receiving oral antibiotics for one week with a diagnosis of tonsillopharyngitis. On physical examination, the left auricle had an edematous, hyperemic, and convex appearance. The postauricular region was erythematous, swollen, and tender. The tympanic membrane was hyperemic and bulged. The patient did not have a history of acute otitis media infection. Complete blood count test revealed a leukocyte count of 12990 cells/mm<sup>3</sup>, peripheral smear test showed 50% polymorphonuclear neutrophils, hemoglobin was 11.3 g/dL, platelet count was 882.000/mm<sup>3</sup>, and C-reactive protein (CRP) was 58 g/L. Immunoglobulin, C3, and C4 levels were normal. In the superficial ultrasound exam-

ination of the patient, there was fluid collection indicating a thick-walled abscess with dimensions of 36 x 10 mm in the left postauricular region, and the surrounding soft tissues had an edematous appearance. Computed tomography (CT) imaging of the temporal bone revealed mastoiditis on the left side and a subperiosteal abscess on the cortical bone (Figure 1A). Percutaneous aspiration was applied to the postauricular region, and subperiosteal abscess drainage was performed. During the procedure, fistulation from the mastoid bone was observed. Purulent material was drained, and a ventilation tube was placed in the left ear. Intravenous vancomycin (60 mg/kg/day) and ceftriaxone (100 mg/kg/day) treatment was initiated. *S. pneumoniae* was yielded in the culture and typed as serotype 19A. Antibiotic susceptibility of the isolate is shown in Table 1.

On the 10<sup>th</sup> day of the antibiotic treatment of the patient with ceftriaxone and vancomycin, a maculopapular rash was observed on his whole skin areas with a plaque-like appearance suggestive of drug rash. The antibiotics were stopped, and the treatment was maintained with linezolid. Total duration of the treatment was extended to four weeks. Mastoiditis was cured without complications, and recovery was confirmed with a control CT (Figure 1B).

### Discussion

After the inclusion of PCV in national immunization programs for infants and children, the incidence of invasive pneumococcal diseases has substantially decreased. In Türkiye, Ceyhan et al. diagnosed 167 cases of invasive pneumococcal diseases, among whom 52 (31.1%) had meningitis, 104 (62.2%) had bacteremia, and 11 (6.6%) had empyema (4). Thirty-three percent of these patients were under the age of two, while 56% of them were under the age of five. The prevalence of their general PCV13 serotypes was detected as 56.2% (94/167). The most frequently encountered serotypes were reported as 19F (11.9%), 1 (10.7%), and 3 (10.1%). In a case-control study, PCV13 was found to be significantly effective



**Figure 1. A.** Increased soft tissue density (white arrow) on the level of the mastoid cells compatible with mastoiditis, thickening of the soft tissue in the preauricular region at the subperiosteal distance (black arrow). **B.** Mastoiditis signs are completely regressed (white arrow), and preauricular soft tissue thickening was significantly regressed in follow-up (black arrow).

**Table 1.** Antibiotic sensitivity panel of the infectious agent

Antibiotic name	Sensitive/Medium	MIC (mg/L)/Zone diameter (mm)
Benzylpenicillin	Resistant	1.0
Ceftriaxone	Resistant	4.0
Clindamycin	Resistant	≥1.0
Levofloxacin	Moderately sensitive	0.5
Linezolid	Sensitive	≤2.0
Moxifloxacin	Sensitive	0.12
Vancomycin	Sensitive	≤0.12
Ampicillin	Resistant	4.0
Trimethoprim/Sulfamethoxazole	Resistant	160.0

against the 19A serotype in children aged two to 59 months (5). In another study that included children presenting with AOM, in comparison to children who were administered only PCV7, those who were administered at least one dose of PCV13 had a lower probability to show colonization of PCV13 serotypes (19A, 7F, 6C) in the nasopharynx (6). Ongkasuwan et al. identified 41 pneumococcal mastoiditis cases, determined the most prevalent serotype as 19A (n= 19), and found the likelihood of mastoiditis caused by 19A isolates to present with subperiosteal abscess and require intraoperative mastoidectomy higher in comparison to mastoiditis caused by non-19A isolates (7). The authors reported that multidrug resistance was common in the 19A isolates and 13 (68%) of the 19A isolates were resistant to all antibiotics that were routinely tested (7). Kaplan et al. reported a significant decrease (21%) in the six additional serotypes included in PCV13 in pediatric AOM cases three years after the vaccine started to be administered (8). In the same study, a 76% decrease was observed in the prevalence of serotype 19A, and 55% of the children from whom serotype 19A was isolated had received <3 doses of PCV13. In order to prevent the spread of serotypes currently not included in vaccination and reinforce immunization efforts against pneumococcal diseases, clinical research on developing higher-valent PCVs is in place, and two vaccines are being reviewed for regulations: a 15-valent PCV (PCV15) that contains the 22F and 33F serotypes in addition to the PCV13 serotypes and a 20-valent PCV (PCV20) that contains five additional serotypes (8, 10A, 11A, 12F, and 15B) in addition to the PCV15 serotypes. These novel formulations for PCVs are expected to find a solution to a rising unmet need by facilitating further protection against emerging serotypes not covered in PCVs that are currently licensed (9).

Crowded living conditions like going to a nursery and recent use of antibiotics increase the risk of carriers of resistant pneumococcal species and invasive disease (10). It was learned that our patient had been using antibiotics for the past one week and went to the nursery for his brother.

Consequently, although PCV13 is included in the National Immunization Program of Türkiye, as physicians, we should still think of penicillin resistant *S. pneumoniae* serotype 19A as a potential cause in complicated mastoiditis in patients who have normal immunity, and the continuation of medical surveys is crucial for vaccination decisions regarding PCV15 and PCV20.

**Informed Consent:** Patient consent was obtained.

**Peer-review:** Externally peer-reviewed.

**Author Contributions:** Concept- SÖ; Design- SÖ; Supervision- AÖP; Resource- MD; Data Collection and/or Processing- BA; Analysis and/or Interpretation- BG, MS; Writing- SÖ; Critical Review- AÖP, SKY.

**Conflict of Interest:** No conflict of interest was declared by the authors.

**Financial Disclosure:** The author declared that this study has received no financial support.

## References

1. Koutouzis EI, Michos A, Koutouzi FI, Chatzichristou P, Parpounas K, Georgaki A, et al. Pneumococcal mastoiditis in children before and after the introduction of conjugate pneumococcal vaccines. *Pediatr Infect Dis J* 2016;35(3):292-6. <https://doi.org/10.1097/INF.0000000000000995>
2. Weil-Olivier C, van der Linden M, de Schutter I, Dagan R, Mantovani L. Prevention of pneumococcal diseases in the post-seven valent vaccine era: A European perspective. *BMC Infect Dis* 2012;12:207. <https://doi.org/10.1186/1471-2334-12-207>
3. Johnson HL, Deloria-Knoll M, Levine OS, Stoszek SK, Freimanis Hance L, Reithinger R, et al. Systematic evaluation of serotypes causing invasive pneumococcal disease among children under five: The pneumococcal global serotype project. *PLoS Med* 2010;7(10):e1000348. <https://doi.org/10.1371/journal.pmed.1000348>
4. Ceyhan M, Aykac K, Gurler N, Ozsurekci Y, Öksüz L, Altay Akisoglu Ö, et al. Serotype distribution of *Streptococcus pneumoniae* in children with invasive disease in Turkey: 2015-2018. *Hum Vaccin Immunother* 2020;16(11):2773-8. <https://doi.org/10.1080/21645515.2020.1747931>
5. Moore MR, Link-Gelles R, Schaffner W, Lynfield R, Holtzman C, Harrison LH, et al. Effectiveness of 13-valent pneumococcal conjugate vaccine for prevention of invasive pneumococcal disease in children in the USA: A matched case-control study. *Lancet Respir Med* 2016;4(5):399-406. [https://doi.org/10.1016/S2213-2600\(16\)00052-7](https://doi.org/10.1016/S2213-2600(16)00052-7)

6. Cohen R, Levy C, Bingen E, Koskas M, Nave I, Varon E. Impact of 13-valent pneumococcal conjugate vaccine on pneumococcal nasopharyngeal carriage in children with acute otitis media. *Pediatr Infect Dis J* 2012;31(3):297-301. <https://doi.org/10.1097/INF.0b013e318247ef84>
7. Ongkasuwan J, Valdez TA, Hulten KG, Mason EO Jr, Kaplan SL. Pneumococcal mastoiditis in children and the emergence of multidrug-resistant serotype 19A isolates. *Pediatrics* 2008;122(1):34-9. <https://doi.org/10.1542/peds.2007-2703>
8. Kaplan SL, Center KJ, Barson WJ, Ling-Lin P, Romero JR, Bradley JS, et al. Multicenter surveillance of *Streptococcus pneumoniae* isolates from middle ear and mastoid cultures in the 13-valent pneumococcal conjugate vaccine era. *Clin Infect Dis* 2015;60(9):1339-45. <https://doi.org/10.1093/cid/civ067>
9. Wasserman MD, Perdrizet J, Grant L, Hayford K, Singh S, Saharia P, et al. Clinical and economic burden of pneumococcal disease due to serotypes contained in current and investigational pneumococcal conjugate vaccines in children under five years of age. *Infect Dis Ther* 2021;10(4):2701-20. <https://doi.org/10.1007/s40121-021-00544-1>
10. Çiftçi E, Doğru Ü, Aysev D, İnce E, Güriz H. Investigation of risk factors for penicillin-resistant streptococcus pneumonia carriage in Turkish children. *Pediatr Internal* 2001;43:385. <https://doi.org/10.1046/j.1442-200X.2001.01422.x>