



What is Your Radiologic Diagnosis?

Radyolojik Tanınız Nedir?

Yusuf Baytar (iD), Elif Günay Bulut (iD)

Department of Radiology, Hacettepe University School of Medicine, Ankara, Turkey

Cite this article as: Baytar Y, Günay Bulut E. What is your radiologic diagnosis? J Pediatr Inf 2021;15(3):e201-e202.

A 15-year-old male patient presents with fever, swelling and pain on the neck ongoing for 4 days. It is found out that antibiotic therapy with a diagnosis of acute tonsillitis was started 2 days ago in another clinic in the patient who has no known disease or any regular drug use. Presenting symptoms of the patient are pulse: 109 beats/min., fever: 37.4°C, and other vital findings of the patient are normal. Physical examination reveals a prominently hypertrophic and limited mouth opening. CT of the neck is performed with IV contrast injection for suspected deep neck infection in the patient in whom leukocytosis and elevated erythrocyte sedimentation rate (Leucocyte= $19.6 \times 10^3/\mu\text{L}$, ESR= 36 mm/h) are detected. 'A left retropharyngeal low density collection with peripheral rim enhancement is seen (arrows) (Images 1 and 2). Moreover, a fluid density extending along the retropharyngeal space at the level of oropharynx and hypopharynx is seen. (arrows) (Images 1B and 2B). What is your diagnosis for the patient whose CT slices are given below?

DIAGNOSIS: Retropharyngeal Abscess and Accompanying Phlegmon/Edema

Short Discussion

Deep neck infections are not rare infections of the childhood, causing serious morbidity and mortality (1). Retropharyngeal and parapharyngeal abscess is the most common deep neck infections of the childhood seen mostly simultaneously. Retropharyngeal abscess develops as a result of suppurative

formed on retropharyngeal lymph nodes due to upper respiratory tract infections such as tonsillitis, otitis, and pharyngitis (2). If treatment is delayed, suppurative lymph nodes are ruptured, leading to retropharyngeal abscess or phlegmon. Early diagnosis is important due to possible complications that can cause life-threatening conditions. In retropharyngeal abscess cases that present with symptoms such as fever, neck pain, limited mouth opening, torticollis, clinical suspicion is significant for diagnosis. Lately, there has been an increase especially in community-acquired *S. aureus*-related infections resistant to methicillin (3). Contrast enhanced neck CT or MRI is beneficial in finalizing the diagnosis, differentiating between retropharyngeal phlegmon and abscess, and detecting the spread and possible complications of the infection (2). For retropharyngeal abscess, diagnosis is made seeing low density fluid collection with well defined peripheral rim enhancement at retropharyngeal space (4). In the differentiation of abscess-phlegmon, wall contrasting in the form of peripheral rim is important.

The slices must be meticulously evaluated in terms of significant complications including repression to the air ways, mediastinitis, internal jugular vein thrombosis, and carotid artery pseudoaneurism. In the treatment of retropharyngeal abscess, close follow-up for the protection of the air way and intravenous antibiotic treatment should be primarily preferred for small abscesses. Surgical drainage is required in large abscess that represses the air way or is unresponsive to medical treatment (5).

Correspondence Address/Yazışma Adresi

Yusuf Baytar

Hacettepe Üniversitesi Tıp Fakültesi,
Radyoloji Anabilim Dalı,
Ankara-Türkiye

E-mail: bayt93@gmail.com

Received: 20.06.2021

Accepted: 19.07.2021

Available Online Date: 02.04.2021

©Copyright 2021 by Pediatric Infectious Diseases and Immunization Society.
Available online at www.cocukenfeksiyon.org

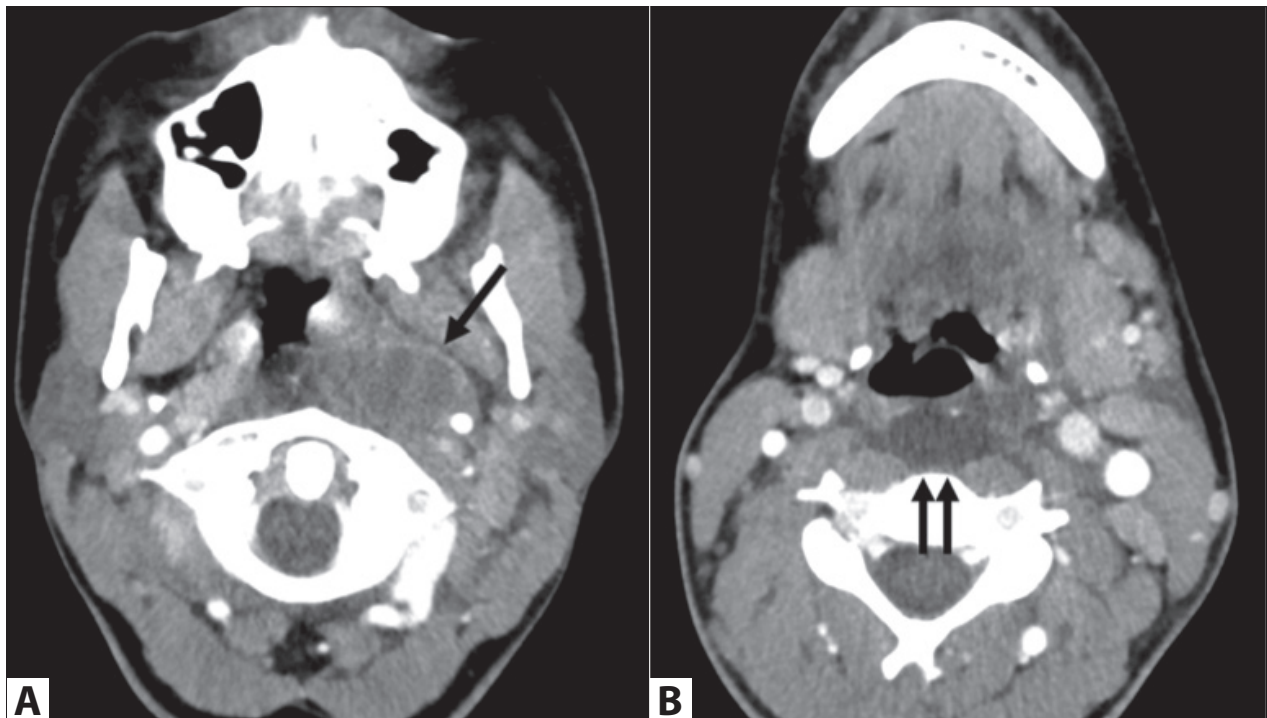


Image 1. Axial contrast neck CT slices of the oropharynx **A.** and hypopharynx **B.**

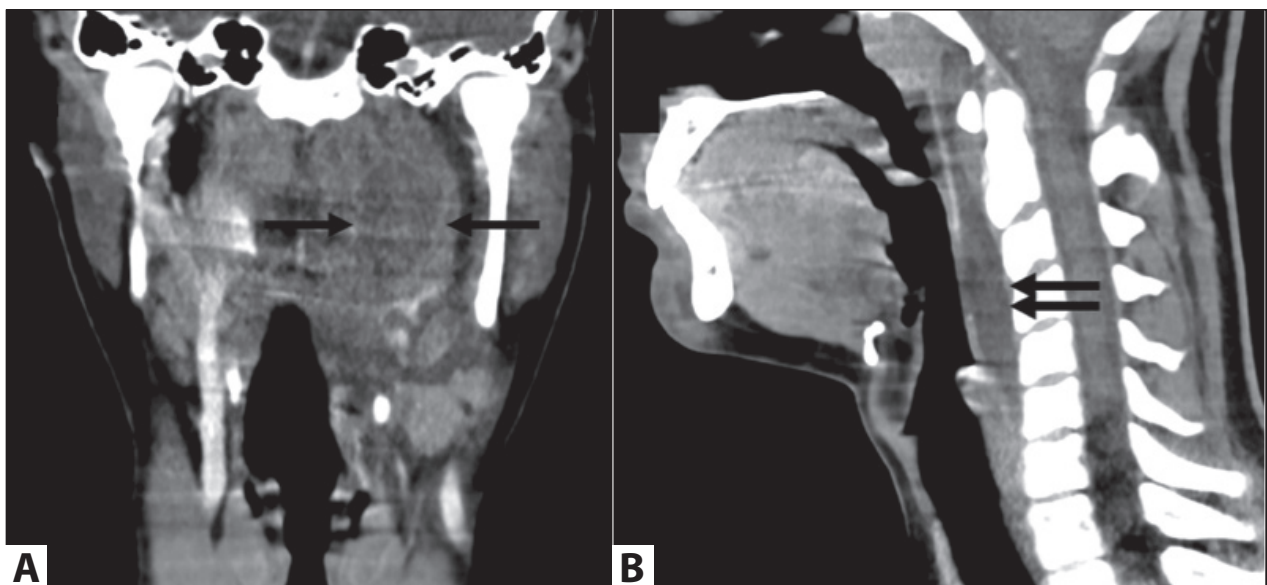


Image 2. Coronal **A.** and sagittal **B.** reformat images of contrast neck CT slices.

References

1. Carbone PN, Capra GG, Brigger MT. Antibiotic therapy for pediatric deep neck abscesses: A systematic review. *Int J Pediatr Otorhinolaryngol* 2012;11:1647-53. [\[CrossRef\]](#)
2. Capps EF, Kinsella JJ, Gupta M, Bhatki AM, Opatowsky MJ. Emergency imaging assessment of acute, nontraumatic conditions of the head and neck. *RadioGraphics* 2010;1335-52. [\[CrossRef\]](#)
3. Abdel-Haq N, Quezada M, Asmar BI. Retropharyngeal abscess in children: The rising incidence of methicillin-resistant staphylococcus aureus. *Pediatr Infect Dis J* 2012;31:696-9. [\[CrossRef\]](#)
4. Ho ML, Courtier J, Glastonbury CM. The ABCs (airway, blood vessels, and compartments) of pediatric neck infections and masses. *AJR* 2016;206:963-972. [\[CrossRef\]](#)
5. Lawrence R, Bateman N. Controversies in the management of deep neck space infection in children: an evidence-based review. *Clin Otolaryngol* 2017;42:156-63. [\[CrossRef\]](#)