



# Primary Solitary and Multiple Intracranial Hydatid Cyst Disease: Report of Four Cases

## Primer Tek ve Çok Sayıda İntrakraniyal Hidatik Kist Hastalığı: Dört Olgu Raporu

Solmaz Çelebi<sup>1</sup>, Şefika Elmas Bozdemir<sup>1</sup>, Özgür Taşkapılıoğlu<sup>2</sup>, Mustafa Hacımustafaoğlu<sup>1</sup>

<sup>1</sup> Department of Pediatric Infectious Diseases, Uludağ University School of Medicine, Bursa, Turkey

<sup>2</sup> Department of Neurosurgery, Uludağ University School of Medicine, Bursa, Turkey

**Cite this article as:** Çelebi S, Bozdemir ŞE, Taşkapılıoğlu Ö, Hacımustafaoğlu M. Primary solitary and multiple intracranial hydatid cyst disease: report of four cases. *J Pediatr Inf* 2018;12(3):e110-e114

### Abstract

Four patients suffered from headache and vomiting at the time of diagnosis. A preoperative diagnosis of the disease was made thanks to cranial magnetic resonance imaging findings and indirect hemagglutination test for *Echinococcus granulosus*. Of these four children, three had cysts in cerebral localization and one in cerebellar localization. Two children had multiple and one of them had recurrent cerebral hydatid disease. All patients received albendazole treatment. While three patients did well after surgical excision, a ventriculoperitoneal shunt was placed in one. Also, this child was operated for duramater defect. Histopathological and microbiological studies were performed for surgical specimens. We consider that primary hydatid disease of brain is still a difficult problem despite all advances in diagnostic methods and surgical techniques.

**Keywords:** Echinococcosis, hydatid cyst, intracranial, childhood

### Öz

İntrakraniyal kist hidatik nadirdir, tüm kist hidatik hastalığının %1-2'sinde bildirilmekte ve çoğu çocukluk döneminde görülmektedir. Bu yazıda, primer intrakraniyal kist hidatik tanılı 4 olgu sunulmuştur. Tanı *Echinococcus granulosus* indirekt hemagglütinasyon testi ve/veya kraniyal manyetik rezonans görüntüleme (MRG) ile konmuştur. Olguların üçünde kist serebral yerleşimli, bir olguda ise serebellar bölgede idi. İki olguda çok sayıda idi, olguların birinde tekrarlayan serebral kist hidatik vardı. Tüm olgulara albendazol tedavisi verildi. Olguların üçü cerrahi operasyon sonrası düzeldi, ancak bir olguya ventriküloperitoneal şant takıldı ve aynı zamanda dura defekti onarıldı. Bu yazı primer serebral kist hidatiğin tanınal ve cerrahi tekniklerin gelişmesine rağmen halen önemli bir problem olduğunu göstermektedir.

**Anahtar Terimler:** Echinococcosis, kist hidatik, intrakraniyal, çocukluk dönemi

### Introduction

Hydatid disease is caused by *Echinococcus granulosus* or *Echinococcus multilocularis* during the larval stage of the tapeworms. The incidence of intracranial hydatid disease is 1-2% of all cases with hydatid disease in all ages. However 50-75% of cases involving the central nervous system occurs in the pediatric age group (1). Cerebral hydatid cysts are usually sol-

itary and may be unilocular or multilocular. Multiple cerebral cysts are rare and usually occur as a result of surgical or traumatic rupture, but spontaneous rupture is also possible (2-9). Multiple cysts resulting from the rupture of a primary cyst are acepholeceles, they are infertile and have no broad capsule. However, very rarely a multiple larval intake may cause primary multiple cerebral hydatid cysts (7,10-12). Hydatid cysts may not cause focal neurological signs until they are very large.

Received: 19.01.2018

Accepted: 12.07.2018

**Correspondence Address / Yazışma Adresi**

**Solmaz Çelebi**

Uludağ Üniversitesi Tıp Fakültesi,  
Çocuk Enfeksiyon Hastalıkları Bilim Dalı,  
Bursa-Türkiye

**E-mail:** solmaz@uludag.edu.tr

©Copyright 2018 by Pediatric Infectious Diseases Society -Available online at [www.cocukenfeksiyon.org](http://www.cocukenfeksiyon.org)

©Telif Hakkı 2018

Çocuk Enfeksiyon Hastalıkları Derneği -Makale metnine [www.cocukenfeksiyon.org](http://www.cocukenfeksiyon.org) web sayfasından ulaşılabilir

Secondary to mass effect, the first clinical sign is usually intracranial hypertension (13).

In this report, we describe four children with primary intracranial hydatid cysts drawing attention to rare and different features of intracranial hydatid disease. The clinical symptoms, medical treatment and surgical interventions of these four children were discussed within the literature.

### Case Report

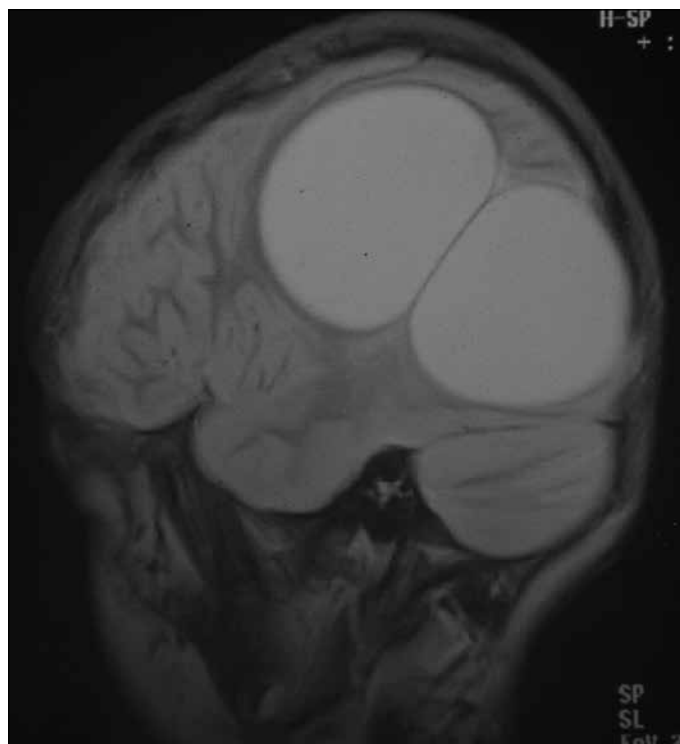This study included four children who were treated for primary intracranial hydatid disease. The clinical and laboratory findings of the patients were reviewed. All four patients, a preoperative diagnosis of the disease was made thanks to cranial Magnetic Resonance Imaging (MRI) findings and indirect hemagglutination test for *E. granulosus*. All patients underwent a chest radiography, abdominal ultrasonography (USG) and echocardiography to reveal if any other localization of hydatid disease was present. Cysts were removed surgically. Histopathological and microbiological studies were performed for surgical specimens. Intraoperative and postoperative complications were documented. Outcome of all patients at least one year after surgical removal were evaluated.

#### Case 1

A 7-year-old boy was admitted to our emergency department with strabismus, headache and vomiting lasting for 3 months. On physical examination esotropia of both eyes and papilledema were detected. The examination of chest radiograph, complete blood count, urine analysis, and blood biochemistry revealed no abnormality. Cranial MRI revealed a large multiloculated intracranial cyst with dimensions of 5.5 x 5,5 x 5 cm in left parieto-occipital region (Figure 1). Investigations for other organ involvement (abdominal ultrasonography, chest radiography and echocardiography) were performed but no other focus was found. Indirect hemagglutination test for *E. granulosus* was positive with 1/256 titer. Albendazole treatment of 10 mg/kg twice daily was started. Upon surgical exploration, the cyst was totally extracted without rupture. Histopathologic examination of the specimen revealed a hydatid cyst with scoleces. Albendazole treatment continued for 3 months till indirect hemagglutination test for *E. granulosus* become 1/32 in titer. The patient is being followed for 3 years and no recurrence of hydatidosis has been detected.

#### Case 2

A 14-year-old boy was admitted to our emergency department in a state of deep stupor. He was suffering from headache, vomiting, malaise and intellectual deterioration lasting for 15 days. The day before hospitalization he had three seizures lasting for about 5 minutes each. He had a history of

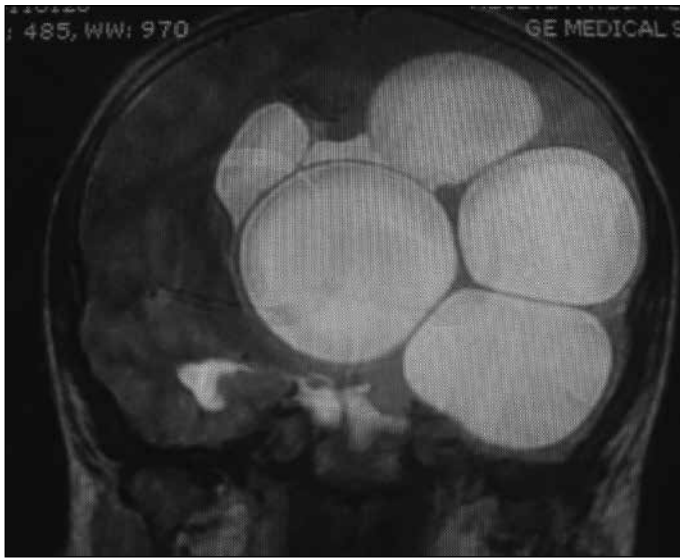


**Figure 1.** T1-weighted image of a multiloculated cyst in the left fronto-temporal region.

surgical intervention for an intracranial hydatid cyst two years ago. On physical examination there was an operation scar on the left frontotemporoparietal area. He could hardly be awakened, without cooperation and orientation. He had bilateral papilledema. The examination of complete blood count, urine analysis, chest radiograph and blood biochemistry revealed no abnormality. Indirect hemagglutination test for *E. granulosus* was positive with 1/64 titer. Cranial CT imaging demonstrated multiple cystic lesions the biggest of which was 6 x 7 x 7 cm in diameter in the left frontotemporoparietal region (Figure 2). Albendazole treatment of 10 mg/kg twice daily was started. Extensive screening for another cyst elsewhere in the body revealed negative results. Chest radiography, echocardiography and abdominal ultrasonography were all normal. A left frontotemporoparietal craniotomy and total excision of six cysts without rupture was done. Histopathologic examination confirmed the surgical specimens were hydatid cysts with scoleces. The postoperative course was uneventful, and the patient showed marked recovery in his neurological status. Postoperative CT confirmed complete excision of the cysts. He got albendazole treatment for three months after operation without any sign of new cysts elsewhere in the body.

#### Case 3

A 15-year-old boy presented to our pediatric outpatient clinic with the history of headache and vomiting of two days duration. He was complaining from headache for a year with

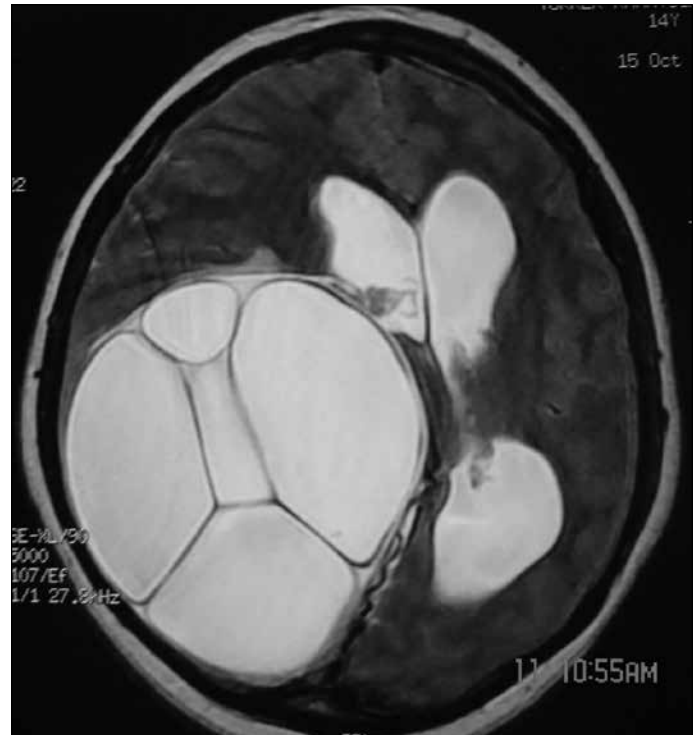

**Figure 2.** Cranial CT image of multipl cysts in frontotemporoparietal region.

augmentation on the last 2 months. On neurological examination he had right temporal hemianopsia and right hemiparesis. Chest radiograph, complete blood count, urine analysis, and blood biochemistry were all normal. Cranial MRI demonstrated multiple cystic lesion of 8 x 9 x 9 cm on the right parieto-occipital region which extended to the convexity causing shift effect on midline structures (Figure 3). Indirect hemagglutination test for *E. granulosus* was positive with 1/2048 titer. Investigations for other organ involvement (abdominal ultrasonography, chest radiography and echocardiography) were performed and no other focus was found. Albendazole treatment of 10 mg/kg twice daily was started. Upon surgical intervention 10 cysts were extirpated without rupture. An external ventricular drainage catheter was placed on the second day after operation and a ventriculoperitoneal shunt was placed on the fifteenth day. Histopathologic examination confirmed the surgical specimens were hydatid cysts with scoleces. Albendazole treatment was given in a dosage of 10 mg/kg twice daily for 6 months. He was hospitalized two times for meningitis in the following year. Further diagnostic evaluations revealed defect in frontobasale part of duramater and he went under surgical repairment. After second operation, no problem is detected in a 2 years follow-up period.

#### Case 4

A 7-year-old boy was admitted to our pediatric emergency department with headache, intermittant vomiting and gait disturbances lasting for 3 weeks. Neurologic examination revealed bilateral papilledema, positive cerebellar signs on the left and cerebellar ataxia. The examination of chest radiograph, complete blood count, urine analysis, and blood biochemistry revealed no abnormality. Cranial MRI revealed a midline cer-

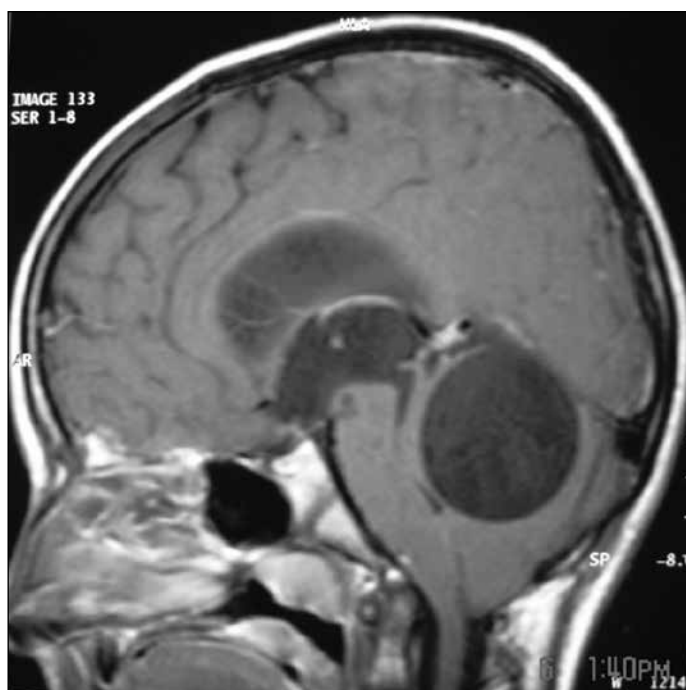

**Figure 3.** T2-weighted image of multipl cysts in right parieto-occipital region which extended to the convexity causing shift effect on midline structures.

ebellar cystic lesion of 4 x 4 cm, which was hypointense on T1-weighted images and hyperintense on T2-weighted images without contrast enhancement (Figure 4). The lesion was compressing the fourth ventricle causing dilation of the third and lateral ventricles. Laboratory studies including complete blood count, urine analysis and blood biochemistry revealed no abnormality. Extensive examination including chest radiography, echocardiography and abdominal ultrasonography for another hydatid cyts were all normal. Indirect hemagglutination test for *E. granulosus* was negative. Albendazole treatment of 10 mg/kg twice daily was started. Although the cyst capsule was ruptured during operation, total removal was achieved. Histopathologic examination of the specimen revealed a hydatid cyst with scoleces. Postoperative MRI confirmed complete excision of the cyst. He has been on albendazole medication for 3 months without any complication.

#### Discussion

In hydatid disease, the main pathogenic species for humans are *E. granulosus* and less frequently *E. multilocularis*. Humans become infected by ingesting tapeworm eggs passed from an infected carnivore; especially dogs; which most frequently happens when individual handle or have a contact with infected carnivores or inadvertently ingest food or drink which is contaminated with fecal material containing tapeworm eggs (14,15). The history of direct contact with dogs was



**Figure 4.** Cranial MRI revealed a midline cerebellar cystic lesion of 4 x 4 cm, which was hypointense on T1-weighted images.

found in patients 2 and 4. However, because our country is an endemic region, all the children in our series may have been infected by eating ingested food or milk.

Intracranial hydatid disease is considered a childhood disease. Fifty percent to 75 percent of intracranial hydatid cysts are seen in children. Izci et al. reported a series of 17 patients with intracranial hydatid cysts and 13 (65%) of these patients were children (16). Cerebral hydatid cysts are often supratentorially localized in the distribution of the terminal branches of the middle cerebral artery, usually temporo-parieto-occipitally (17,18). In our series, three patients had cysts in the distribution of middle cerebral artery; one in left parieto-occipital region, one in right parieto-occipital region and one in left fronto-temporo-parietal region.

Intracranial hydatid cysts may also be classified as primary or secondary. The primary cysts are formed as a result of direct infestation of the larvae in the brain without demonstrable involvement of other organs. In primary multiple cysts, each cyst has a separate pericyst with brood capsule scoleces and these originate from multiple larvae affecting brain after crossing the gastrointestinal tract, liver, lungs and right side of heart without affecting them. The primary cysts are fertile as they contain scoleces and brood capsules, hence rupture of primary cyst can result in recurrence. The secondary multiple cysts results from spontaneous, traumatic or surgical rupture of the primary intracranial hydatid cyst and they lack brood capsule and scoleces. The secondary intracranial hydatid cysts

are therefore, infertile and the resultant risk of recurrence after their rupture is negligible. Primary multiple cysts are uncommon and isolated case reports of primary multiple hydatid cysts have appeared in the literature (19,20). Onal et al. found only three cases of multiple cysts in their series of 33 cases and Lunardi et al. found 2 cases in their series of 12 cases. In our series, two patients had multiple intracranial hydatid cysts (21,22). One of these patients had 10 primary cysts in right parietooccipital region. The other child had a history of operation for a solitary intracranial hydatid cyst without rupture two years before being operated in our pediatric neurosurgery department. In the second operation 6 hydatid cysts, the biggest of which was 6 x 7 x 7 cm in diameter were removed from the left frontotemporoparietal region. Because the histopathological evaluation of these cysts removed in the second operation revealed scoleces, and the surgical data of the first operation did not mention about rupture, we consider this patient has experienced recurrent intracranial hydatid disease due to multiple larval intake.

The patients with intracranial hydatid cysts usually present with focal neurological deficit and features of raised intracranial pressure; the latter may be due to the large size or due to interference with pathway of cerebrospinal fluid flow. Ersahin et al. observed that 18 out of 19 cases presented with raised intracranial pressure (1). In our series, all four patients had symptoms and signs of increased intracranial pressure. All our patients suffered from headache and vomiting. Three patients had bilateral papilledema, one of them had seizures. One patient had right temporal hemianopsia and right hemiparesis.

Radiological evaluations of hydatid cysts by cranial CT scan and MR images reveal solitary, homogeneous, spherical and large parenchymal cysts with well-defined borders, without perifocal edema and environmental contrast enhancement. The density of the cyst fluid is the same as that of cerebrospinal fluid (23). In our cases, three patients were evaluated with cranial MRI and one patient with cranial CT before operation. Both techniques were helpful in the diagnosis.

The treatment of hydatid cyst is surgical and the aim of surgery is to excise the cyst in total without rupture to prevent recurrence and anaphylactic reaction. Only a few reports are available mentioning the efficacy of drug therapy alone. Isolated case reports showed complete disappearance of multiple intracranial hydatid cysts with Albendazole therapy in a daily dose of 10 mg/kg, taken three times a day for four months (24-26). Preoperative and postoperative albendazole treatment may be considered to sterilize the cyst, decrease the chance of anaphylaxis, decrease the tension in the cyst wall (thus reducing the spillage during surgery), and reduce the recurrence rate (25,27-29). Intact removal rate of hydatid

cyst is around 60-70% (19). In our cases, all patients were operated and total surgical removal was possible. Albendazole treatment was started to all our patients before the operation and continued for at least 3 months after operation. The cyst capsule was ruptured in one patient.

In conclusion, infection with *E. granulosus* should be included in the differential diagnosis for unspecific neurologic symptoms such as progressive headache, especially in pediatric patients where hydatid disease is endemic. The most important issue in cases with intracranial hydatid cysts is whether hydatidosis will develop in the primary sites. These patients should be followed, paying close attention to this possibility.

**Informed Consent:** Written informed consent was not taken from the parents of the patients.

**Peer-review:** Externally peer-reviewed.

**Author Contributions:** Concept - SÇ; Design - SÇ, ŞEB; Supervision - ÖT, MH; Data Collection and/or Processing - SÇ, ŞEB; Analysis and/or Interpretation - ÖT, MH; Literature Review - SÇ, ŞEB; Writing - SÇ; Critical Review - ÖT, MH.

**Conflict of Interest:** The authors have not reported a conflict of interest.

**Financial Disclosure:** The authors declared that this study has received no financial support.

## References

- Ersahin Y, Mutluer S, Guzelbag E. Intracranial hydatid cysts in children. *Neurosurgery* 1993;33:219-25.
- Kaya U, Ozden B, Turker K, Tarcan B. Intracranial hydatid cysts. Study of 17 cases. *J Neurosurg* 1975;42:580-4.
- Krajewski R, Stelmasiak Z. Cerebral hydatid cyst in children. *Childs Nerv Syst* 1991;7:154-5.
- Pasaoglu A, Orhon C, Akdemir H. Multiple primary hydatid cysts of the brain. *Turk J Pediatr* 1989;31:57-61.
- Popli MB, Khudale B. Primary multiple hydatid cysts of the brain. *Australas Radiol* 1998;42:90-1.
- Sahin-Akyar G. Computed tomography and magnetic resonance imaging findings in cerebral hydatid disease. *Radiography* 2002;8:251-8.
- Topal U, Parlak M, Kilic E, Sivri Z, Sadikoglu MY, Tuncel E. CT and MRI findings in cerebral hydatid disease. *Eur Radiol* 1995;5:244-7.
- Tuzun M, Altinors N, Arda IS, Hekimoğlu B. Cerebral hydatid disease CT and MR findings. *J Clin Imaging* 2002;26:353-7.
- Yuceer N, Guven MB, Yilmaz H. Multiple hydatid cysts of the brain: a case report and review of the literature. *Neurosurg Rev* 1998;21:181-4.
- Baysefer A, Erdoğan E, Gönül E, Kayali H, Timurkaynak E, Seber N. Primary multiple hydatid cysts: Case report with CT and MRI study. *Minim Invasive Neurosurg* 1998;41:35-7.
- Bilge T, Batur S, Aydin Y, Aksoy B, Senol S. Primary multiple hydatid cysts of the brain. Case report. *Surg Neurol* 1993;39:377-9.
- İplikcioglu AC, Oze AF, Benli K, Isik N, Erben A. Multiple intracranial hydatid cysts: Report of two cases. *Br J Neurosurg* 1989;3:217-9.
- Sierra J, Oviedo J, Berthier M, Leiguado R. Growth rate of secondary hydatid cysts of the brain. Case report. *J Neurosurg* 1985;62:781-2.
- Altinors N, Baybek M, Caner HH, Erdoğan B. Central nervous system hydatidosis in Turkey: a cooperative study and literature survey analysis of 458 cases. *J Neurosurg* 2000;93:1-8.
- Turgut M. Intracranial hydatidosis in Turkey: its clinical presentation, diagnostic studies, surgical management and outcome. A review of 276 cases. *Neurosurg Rev* 2001;24:200-8.
- Izci Y, Tüzün Y, Seçer H, Gönül E. Cerebral hydatid cysts: technique and pitfalls of surgical management. *Neurosurg Focus* 2008;24:E15.
- Ciurea AV, Fountas KN, Coman TC, Machinis TG, Kapsalaki EZ, Fezoulidis NI, et al. Long-term surgical outcome in patients with intracranial hydatid cyst. *Acta Neurochir (Wien)* 2006;148:421-6.
- Mingde Q, Zheshang H. Echinococcosis of the central nervous system. *Chin Med J* 1980;93:269-74.
- Nurchi G, Floris F, Montaldo C, Mastio F, Peltz T, Coraddu M. Multiple cerebral hydatid disease: case report with magnetic resonance imaging study. *Neurosurgery* 1992;30:436-8.
- Sharma A, Abraham J. Multiple giant hydatid cysts of the brain-case report. *J Neurosurg* 1982;57:413-5.
- Onal C, Barlas O, Orakdögen M, Hepgül K, Izgi N, Unal F. Three unusual cases of intracranial hydatid cysts in paediatric age group. *Pediatr Neurosurg* 1997;26:208-13.
- Lunardi P, Missori P, Di-Lorenzo N, Fortuna A. Cerebral hydatidosis in childhood: a retrospective survey with emphasis on long term follow up. *Neurosurgery* 1991;29:515-8.
- Okten A, Ergun R, Gezeran Y. Primary intracranial extradural hydatid cyst localized in the supra- and infra-tentorium. *Acta Parasitol* 2006;51:309-10.
- Altas M, Aras M, Serarslan Y, Davran R, Evirgen O, Yilmaz N. A medically treated multiple cerebral hydatid cyst disease. *J Neurosurg Sci* 2010;54:79-82.
- Singounas EG, Leventis AS, Sakas DE, Hadley DM, Lampadarios DA, Karvounis PC. Successful treatment of intracerebral hydatid cysts with albendazole: Case report and review of literature. *Neurosurgery* 1992;31:571-4.
- Todorov T, Vutova K, Petkov D. Albendazole treatment of multiple cerebral hydatid cysts: a case report. *Trans R Soc Trop Med Hyg* 1988;82:150-2.
- Boop FA, Jacops RF, Young RL. Brain abscess and encephalitis in children. In: Albright AL, Pollack ID, Adelson PD (eds). *New York: Principles and Practice of Pediatric Neurosurgery*, 1999:1203-26.
- Horton RJ. Albendazole in treatment of human echinococcosis: 12 years of experience. *Acta Trop* 1997;64:79-93.
- Tuzun Y, Kadioglu HH, Izci Y, Suma S, Keles M, Aydin IH. The clinical, radiological and surgical aspects of cerebral hydatid cysts in children. *Pediatr Neurosurg* 2004;40:155-60.